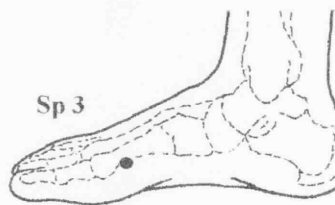
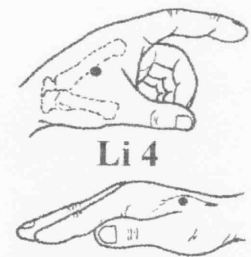
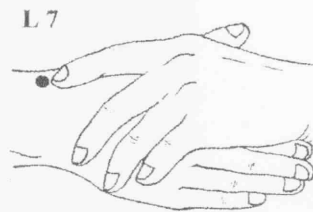
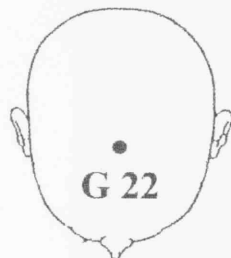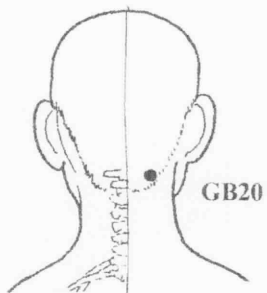
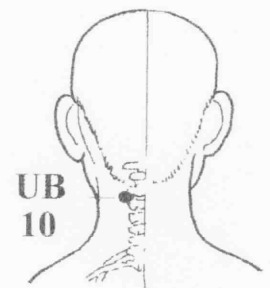
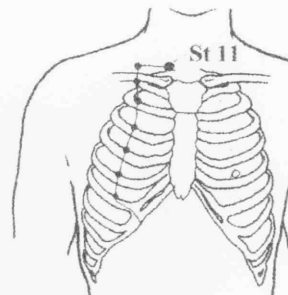
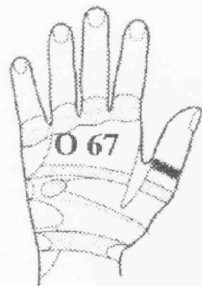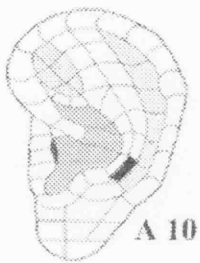
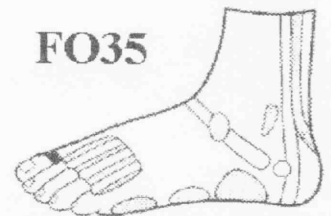


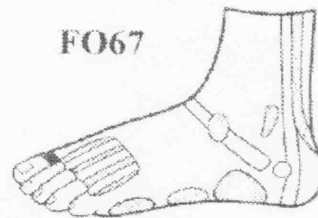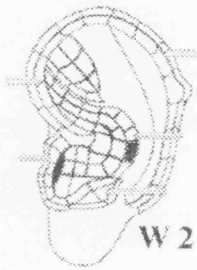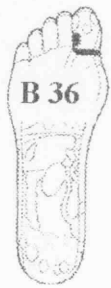# AcuPoint Analysis THYROID

## Points



**AcuPoint Analysis**  
**THYROID**  
(DESCRIPTIONS)

Point	Description
<b>C22</b>	In the center of the depression above the supraorbital notch, the pressure being applied downward alongside the trachea.
<b>EA10</b>	Upper Anterior Neck Muscles, Torticollis, Chinese Thyroid Gland. Located on the 10th zone of the Antihelix.
<b>EW02</b>	Middle and Inferior Cervical Sympathetic Ganglia, Thyroid Gland, Wonderful Point. Located on the 2nd zone of the Wall of the Antihelix.
<b>FB36</b>	Neck, side of . Bottom of foot on both sides.
<b>FO35</b>	Neck. On big toe.
<b>FO67</b>	Thyroid. On big toe.
<b>G22</b>	On the midline of the skull 3 cun in front of a line connecting the tops of the ears.
<b>GB20</b>	This point is right under and against the base of the skull, in the two small muscular grooves at the back of the neck, two to three inches apart depending on the size of the head.
<b>HO67</b>	Thyroid.
<b>LI04</b>	On the back of the hand between the thumb and index finger metacarpal bones. Find the spot midway on the bone that connects the index finger to the wrist and probe inward toward the main body of the hand.
<b>LU07</b>	On thumb edge of the wrist, 1.5 Cun toward elbow from wrist crease nearest hand. A difficult point to find, but made easier by linking the hands (in picture), find point beneath index finger lying along top of wrist, deep in a small hollow.
<b>SP03</b>	On the inside of the foot just behind the large bulging joint of the big toe. On the metatarsal bone.
<b>ST11</b>	Just above the inside end of the clavicle.
<b>UB10</b>	0.5 cun just beneath the base of the skull, on the ropy muscles and 0.5 cun from the spine midline.